

## Case Report

### Human fascioliasis: A diagnostic challenge in resource limited setting

Brook Alemayehu <sup>1</sup>, Zekewos Demissie <sup>1</sup>, Eyob Beyene <sup>2</sup>

<sup>1</sup> Assistant professor of Internal Medicine, Lancet General Hospital, Addis Ababa, Ethiopia

<sup>2</sup> Department of Internal Medicine, Division of Infectious Disease, College of Health Sciences, Addis Ababa University, Addis Ababa, Ethiopia

Corresponding authors\*: brookalemayehul@gmail.com

#### Abstract

*Fascioliasis, a disease caused by liver flukes. It is one of the neglected zoonotic diseases. There are only a few reports of fascioliasis from Ethiopia and no case with predominant extrahepatic presentation has been reported so far. We report a case of young woman, who presented with a two weeks of dry cough and generalized pruritus. Her workup revealed marked eosinophilia and multiple, hypodense, and hypovascular hepatic lesions. An enzyme-linked assay became positive for Fasciola hepatica. Fasciola hepatica can present with predominant extra hepatic presentation and should be considered in patients presenting with urticaria, skin rash, cough and eosinophilia*

**Keywords:** Human fascioliasis, Fasciola hepatica, Liver Fluke, Eosinophilia, Extrahepatic

**Citation :** Alemayehu B, Demissie Z, Beyene E. Human fascioliasis: A diagnostic challenge in resource limited setting. *Ethiop Med J* 61 (4) 391- 394

**Submission date :** 12 July 2023 **Accepted:** 2 August 2023 **Published:** 42 September 2023

#### Background

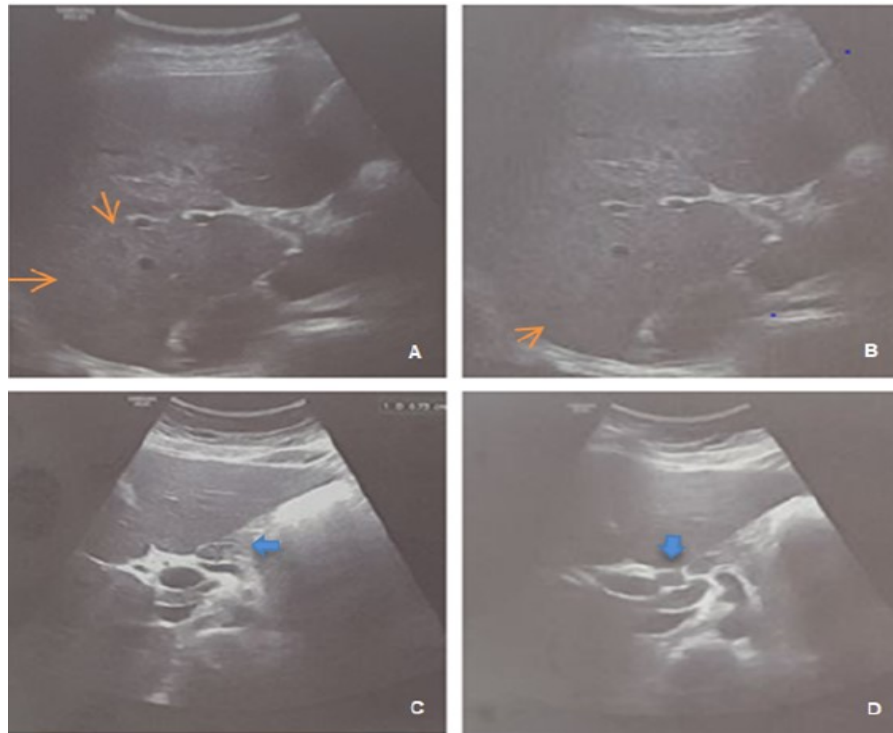
Fascioliasis is a trematode disease caused by two species, fasciola hepatica and fasciola gigantica [1]. It has been predicted that 2.6 million people are infected with Fasciola spp [2]. Despite reported world-wide distribution of fascioliasis, data from Africa is scanty [3]. In Ethiopia, fascioliasis is one of the major livestock diseases, particularly of ruminants [4]. This report describes a young woman presented predominantly with extrahepatic features of fascioliasis.

#### Case Description

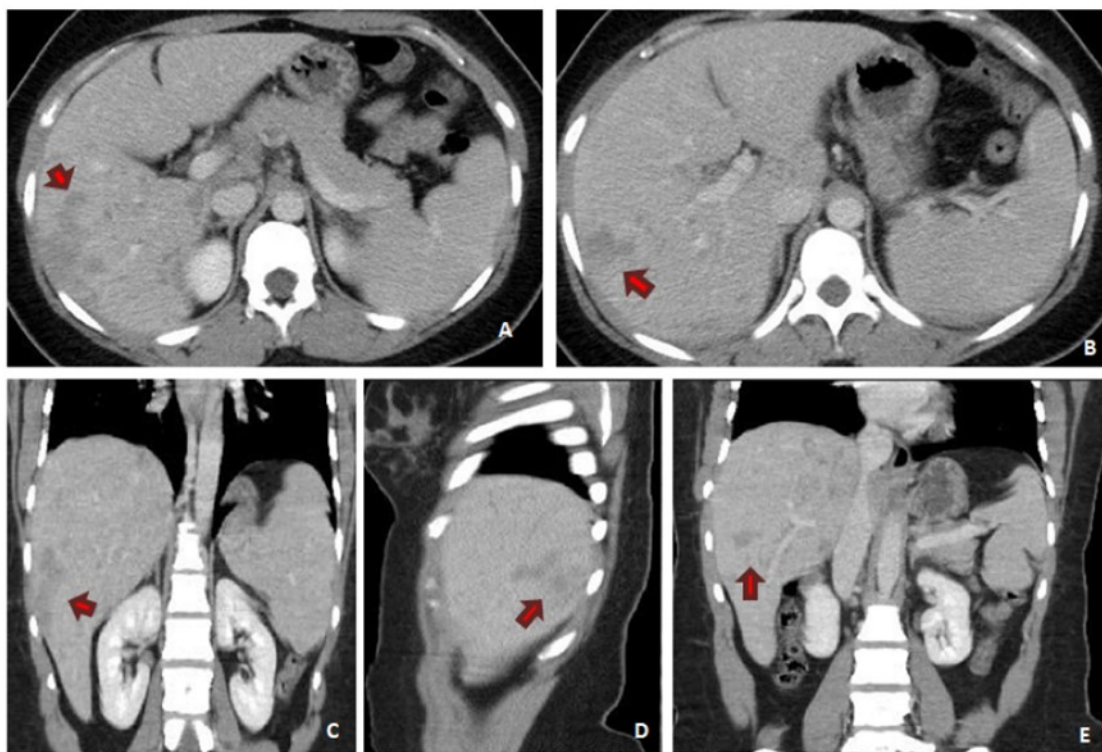
A 34-years-old woman from Addis Ababa presented with a dry cough and pruritus of 2 weeks duration. She developed pruritic urticarial cutaneous lesions involving the whole body sparing her face, palms, and soles. Over the following week, she started to have pain over the mid back and bilateral flank followed by vomiting of ingested and bilious matter. Her symptoms started a month after a leisure-travel to Bishoftu city and remembered eating salad consisting of lettuce and tomato.

On presentation, she was in severe pain and her physical examination was normal. Laboratory revealed white blood cell count of 16,360 cells per microliter with an absolute eosinophil count of 10,550 cells per microliter. Organ function tests, stool examination, urinalysis and pancreatic enzymes were within normal range. Viral markers for hepatitis B and C and HIV were negative. Her chest radiograph was unremarkable.

The initial ultrasound showed multiple small hepatic nodules (Figure 1 A, B) with periportal lymphadenopathies (Figure 1 C, D). Subsequently, abdominal computed tomography (CT) scan with intravenous contrast was obtained and it revealed multiple, ill-defined, hypodense, and hypovascular hepatic lesions (Figure 2A-E).



**Figure 1:** A& B show multiple hepatic nodules involving a few hepatic segments (orange arrows) with multiple periportal lymphadenopathies noted (blue arrows) as seen in C & D



**Figure-2:** (A-E) Multiple, variable sized, ill-defined hypo-enhanced hepatic lesions affecting predominantly the right lobe (red arrows). The lesions are mainly peripheral but have periportal and perivascular best seen in the portal venous phase (red arrows) with progressive enhancement in the delayed phase.

In light of the patient's travel history and eosinophilia, serologic workups were pursued. Repeated stool examinations were non-revealing. Serologic results became negative for *Toxocara canis* antibody (IgG) and *fasciola hepatica* IHA was reported positive with a titer of 1:2560 (Ref. Range < 1:160) and *fasciola hepatica* IgG of 39.9U/ml (Ref. Range < 9.0U/ml) confirming the diagnosis of *fasciola hepatica*.

Oral triclabendazole was started and she had clinical improvement including the resolution of cough, pruritus, skin lesions and the pain. Weekly monitoring of eosinophil count and abdominal ultrasound showed a progressive decline. After 3 weeks the eosinophil count dropped to 1830 cells per microliter and -liver nodules disappeared.

### Discussion

Human fascioliasis is a food-borne trematode infection. Humans are incidental hosts and become infected by ingesting raw fresh plants carrying metacercariae [1]. Fascioliasis has two clinical phases, the initial acute (liver) phase and the chronic (biliary) phase. The acute phase is due to damage to hepatocytes directly from the mature flukes. At this stage patients present with fever, anorexia, nausea, vomiting, right upper quadrant pain, and hepatitis. Allergic and immunologic responses may result in Leofflers syndrome, pruritic urticaria, pericarditis, and meningitis. Marked peripheral eosinophilia is almost always present [6, 7].

The chronic phase results from obstruction of the biliary tree and resultant inflammation. It is characterized by intermittent biliary colic, jaundice, and diarrhea. The chronic phase can be complicated by cholangitis, cholelithiasis, and obstructive jaundice. Pancreatitis is also reported in 30 percent of cases [6].

### References

1. Mas-Coma S. Epidemiology of fascioliasis in human endemic areas. *J Helminthol*. 2005 Sep;79(3):207-16. doi: 10.1079/joh2005296. PMID: 16153314.
2. Webb CM, Cabada MM. Recent developments in the epidemiology, diagnosis, and treatment of *Fasciola* infection. *Curr Opin Infect Dis*. 2018 Oct;31(5):409-414. PMID: 30113327.
3. Dermauw V, Muchai J, Al Kappany Y, Fajardo Castaneda AL, Dorny P. Human fascioliasis in Africa: A systematic review. *PLoS One*. 2021 Dec 9;16(12):e0261166. doi: 10.1371/journal.pone.0261166. PMID: 34882738; PMCID: PMC8659297.
4. Fentie T, Erqou S, Gedefaw M, Desta A. Epidemiology of human fascioliasis and intestinal parasitosis among schoolchildren in Lake Tana Basin, northwest Ethiopia. *Trans R Soc Trop Med Hyg*. 2013 Aug;107(8):480-6. doi: 10.1093/trstmh/trt056. PMID: 23843557.
5. Adachi S, Kotani K, Shimizu T, Tanaka K, Shimizu T, Okada K. Asymptomatic fascioliasis. *Intern Med*. 2005 Sep;44(9):1013-5. PMID: 16258225.
6. López-Vélez R, Domínguez-Castellano A, Garrón C. Successful treatment of human fascioliasis with triclabendazole. *Eur J Clin Microbiol Infect Dis*. 1999 Jul;18(7):525-6. PMID: 10482035.
7. Marcos LA, Terashima A, Gotuzzo E. Update on hepatobiliary flukes: fascioliasis, opisthorchiasis and clonorchiasis. *Curr Opin Infect Dis*. 2008 Oct;21(5):523-30.
8. Caravedo MA, Cabada MM. Human Fascioliasis: Current Epidemiological Status and Strategies for Diagnosis,

There is no gold standard diagnostic modality for fascioliasis [8]. The diagnosis is made by positive serology and imaging that reveals acute, hypodense liver lesions that change over time [9]. On imaging small, multiple, nodular lesions are suggestive of fascioliasis. These lesions are hypoechoic on ultrasound, hypodense on CT scan, and T2 hyper- and T1 hypointense on magnetic resonance imaging (MRI) [10].

Triclabendazole is the drug of choice for its effectiveness against both adult and immature worms. Bithionol and nitazoxanide are alternative choices [6].

### Conclusion

Human fascioliasis has variable clinical presentation and may mimic many clinical conditions. Infestations with parasites are frequent in developing countries. However, they are often misdiagnosed as other conditions. Maintaining a high index of suspicion is very important in reaching the diagnosis. The presence of allergic manifestations and eosinophilia should mandate a consideration of acute fascioliasis in at risk individuals.

### Ethical issues

Written informed consent was obtained from the patient for publication of this case and related photographic evidence.

### Acknowledgment

We are grateful to our patient for providing the necessary information.

### Disclosure

The authors report no conflicts of interest.

- Treatment, and Control. *Res Rep Trop Med.* 2020 Nov 26;11:149-158.
9. Kabaalioglu A, Cubuk M, Senol U, Cevikol C, Karaali K, Apaydin A, Sindel T, Lüleci E. Fascioliasis: US,CT, and MRI findings with new observations. *Abdom Imaging.* 2000;25:400–404.
  10. Koç Z, Ulsan S, Tokmak N. Hepatobiliary fascioliasis: imaging characteristics with a new finding. *Diagn Interv Radiol.* 2009 Dec;15(4):247-51.