

CASE REPORT**HYDATID CYST DISEASE IN THE LEFT LATERAL NECK:
AN UNCOMMON PRESENTATION**Engida Abebe, MD,^{1*} Ayeligh Tsehay MD¹**ABSTRACT**

Cysts commonly occurring in the neck include thyroglossal cyst and dermoid cysts in the midline, cystic thyroid nodules, branchial cysts and cystic Hygroma in the lateral neck. Hydatid cyst disease is commonly seen in the right lobe of the liver, the lung and rarely in other parts of the body. In general, cysts in the neck are not common in the second decade of life. In this article, we present a case of hydatid cyst presenting as left lateral cystic mass in an Ethiopian boy. The diagnostic difficulty, the need for diagnostic suspicion and consideration of hydatid cyst in the differential diagnosis and the management options are discussed.

Key words : Hydatid cyst, Neck, Fine needle aspiration cytology, Ethiopia.

INTRODUCTION

Hydatid Cyst (HC) is a parasitic disease caused by the tape worm *Echinococcus*. Six types of *Echinococcus* species are known, of which two of the species cause Hydatid disease in humans. *Echinococcus granulosus* (EG) causes cystic echinococcosis/HC, while *Echinococcus multilocularis* causes alveolar echinococcosis (1,2). EG is the most common form and has worldwide distribution, being endemic in sheep rearing areas. The prevalence of the disease varies from region to region but is most commonly seen in Latin America, the Middle East, other parts of Asia and Sub-Saharan African countries (1,2). Reports from Ethiopia showed HC infection rate in animal's abattoirs to be significant. As more than 85% of Ethiopians are farmers and have strong contact with sheep and dogs, human infestation rate is expected to be high (3,4).

The life cycle of *Echinococcus* includes a definitive host, usually dogs or related species and an intermediate host such as sheep, goats or swine. Humans are incidental hosts and do not play a role in the transmission cycle. Transmission frequently occurs in settings where dogs eat the viscera of slaughtered animals. The dogs then excrete infectious eggs in their feces, which are passed on to other animals or humans via fecal-oral route. This may occur via environmental contamination of water and cultivated vegetables, or contact between infected domestic dogs and humans, often

during childhood (1,2). Following egg ingestion by the intermediate or incidental host, the Oncospheres hatch from the eggs, penetrate the intestinal mucosa, enter the blood and/or lymphatic system, and migrate to the liver or other visceral organs (1,2).

Infection with EG cause one or several unilocular HC that in humans develops mainly in the liver (70%) and lungs (20%). The rest, 10% of cysts can occur almost anywhere in the body, including the brain, body musculature, wall of the heart, kidneys, spleen, pancreases, orbit of the eye and marrow cavity of bones (1, 5).

In this paper we present a 16 years old boy who presented with left lateral cystic mass which was found to be HC only after surgery. The diagnostic difficulty, the need to consider HC in the differential diagnosis and the management options are discussed.

CASE REPORT

A 16 years old boy detected a left lateral neck swelling while taking a shower four months before presentation. The swelling showed a very slow increase in size. The patient had no swelling in other part of the body. He had no chest or abdominal complaint. He had contact with dogs and cats at home. On physical examination the only abnormal finding was a left lateral lower neck cystic swelling measuring three by

¹ Department of Surgery, St. Paul's hospital Millennium Medical college

* Corresponding author: engidaabebe@yahoo.com

five centimeter (cm) behind the sternocleidomastoid (SCM). The lower border was not felt.

A complete blood count was normal, ultrasound (US) showed septated cystic mass deep to the SCM (Figure 1). Fine needle aspiration cystology (FNAC) showed sheets of macrophage disposed in fluidy background and concluded cyst with no special feature. With an assessment of cystic neck mass patient was prepared for excisional biopsy.

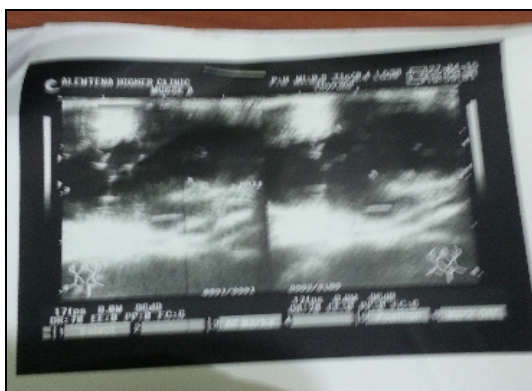

Figure 1- Ultrasound of the neck – showing cystic neck mass with septations

Under general anesthesia pillow under the shoulder neck was prepared and a supra-clavicular skin crease incision made. After subplatysmal skin flaps rose the cyst was found behind the SCM, which was split and cyst extent assessed. The cyst extended for two to three cm below the clavicle and had a thick wall. The cyst was dissected carefully and completely removed. During the surgery there was micro-perforation resulting cyst fluid leakage. At the end of the procedure the cyst was opened and found to have multiple daughter cysts, a germinal layer and an outer layer (ectocyst) (Figure 2).

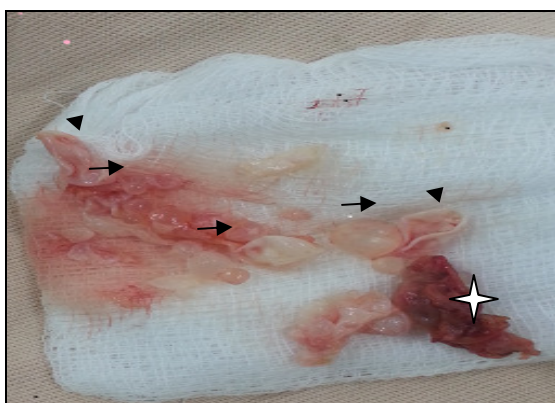


Figure 2 - the opened specimen showing
 1. Multiple daughter cysts - the arrow
 2. The two pieces of the germinal layer (Endocyst) - arrow head
 3. The Exocyst with the host derived adventitial layer (Peri-cyst) - the star

Though there was leakage of cyst fluid, the patient didn't show any allergic reactions. Patient had uneventful post-operation course and started with albendazole on the first post-operation day. In the subsequent days, an abdominal ultrasound and a chest x-ray were done and showed no abnormality. During follow-up, the patient had a smooth course and there was no sign of recurrence.

DISCUSSION

HC disease is a fairly common condition in the developing countries including Ethiopia, especially in those who have frequent contact with dogs and sheep (1). In general cysts in the neck are not common. HC in the neck is even less common that physicians or surgeons don't consider it as a differential diagnosis of cysts in the neck (6), which was the case in our patient. Though uncommon outside the liver and the lung, there are reports of the disease almost in every part of the body including the neck, mostly on the left lower lateral neck (6-8). Parasite eggs that penetrate the organism hatch in the small intestine of the host, pass into portal venous system or lymphatic system and reach the organ or tissue affected. In the neck, the most commonly reported site for HC is left lateral lower neck probably due to spread through the thoracic duct (9).

Though it is a rare clinical condition, considering HC in the work up of patients with cystic neck mass is important. US is an excellent imaging option but if no high index of suspicion it can miss diagnosis (9). Computerized tomography (CT) scanning and magnetic resonance imaging (MRI) are other options to consider. US was found to be better than both CT and MRI in diagnosing and staging of abdominal HC (10). Findings of HC on US depend on the growth stage of the cyst (i.e., whether the cyst is unilocular, containing daughter vesicles and daughter cysts and is partially calcified or is completely calcified). Shah DS described US finding of HC in the liver, which also applies to other sites accessible by US (11). In our case, US was done by an experienced radiologist but didn't suggest the possibility of HC most likely because the disease is rare and not considered as a possibility by the radiologist and the physician requesting the US examination.

FNAC is an area of controversy because there is a risk of anaphylactic shock as a result of fluid leakage or spillage. Reports show HC of the neck can be diagnosed by FNAC (12,13). Chakrabarti I, et al. diagnosed HC by FNAC in a 42 years old man suspected to have cold abscess on clinical grounds. In his case

the microscopic examination revealed scolices and hooks with few fragments of lamellar membrane in a dirty background of pus cells and cell debris. This helped to further work up the patient and initiate albendazole preoperatively (13). Recommended immunologic/serologic investigations include indirect hemagglutination, latex agglutination, enzyme linked immunosorbent assay (ELISA) and immunoelectrophoresis (9). None of these were done pre-operatively in our case.

Several options of treatment are described for the treatment of HC, including surgical excisions, percutaneous aspiration and injections of hypertonic saline and aspiration, percutaneous injection of albendazole

without aspiration and albendazole only (14). The most effective treatment for neck HC is surgical excision. If diagnosed pre-operatively, albendazole should be given for at least four days before surgery. Complete cyst removal has an excellent outcome (9,13). During surgery, care should be given to avoid rupture of the cyst and, in case it does, anesthetists should be informed for there is a risk of anaphylactic shock. Surgery may be the only treatment needed when the cyst didn't rupture and is removed completely (13,15). If the cyst ruptures or cyst fluid leaks, to avoid recurrence, albendazole needs to be continued for at 6 weeks (15).

REFERENCES

1. Grosso G, Gruttadauria S, Biondi A, Marventano S, Mistretta A. Worldwide epidemiology of liver hydatidosis including the Mediterranean area. *World J Gastroenterol* 2012;18(13):1425-37
2. Leder K, Weller P. Life cycle and epidemiology of echinococcal species. UpToDate 2011;19.3. Accessed at <http://cursoenarm.net/UPTODATE/contents/mobipreview.htm/>
3. Abera M, Teame S, Sheferaw D. Cystic Echinococcosis of Cattle in Jimma Municipal Abattoir, South West Ethiopia. *Global Veterinaria* 2013;11(6):771-5.
4. Degefu H, Damet T. Hydatidosis of cattle and sheep, its economic importance and *Echinococcus granulosus* among stray dogs in South Wollo, Ethiopia. *Ethiop Vet J* 2013;17(2),101-19
5. Minas M, Biluts H, Bekele A, Alemie M. Surgical management of 234 patients with hydatid disease: the Tikur Anbessa Hospital experience. *Ethiop Med J*. 2007;45(3):257-65.
6. Mahesh K, Mittal M, Amita M, et al. Cystic masses of neck: A pictorial review. *Indian j Radiol Imaging* 2012;22(4):334-43)
7. Abu-Eshy SA. Some rare presentations of hydatid cyst (*Echinococcus granulosus*). *J R Coll Surg Edinb*; 1998;43(5):347-52.
8. Ahmad S, Jalil S, Saleem S, Suleman B, Chughtai N. Hydatid cysts at unusual sites: Reports of two cases in the neck and breast. *J Pak Med Assoc*. 2010;60(3):232-4.
9. Iynena I, Sogutb O, Guldurc M, Kosed R, Kayab H, Ferhat Bozkus. Primary Hydatid Cyst: An Unusual Cause of a Mass in the Supraclavicular Region of the Neck. *J. Clin Med Res* 2011;3(1):52-54
10. Stojkovic M, Rosenberger K, Kauczor H-U, Junghanss T, Hosch W (2012) Diagnosing and Staging of Cystic Echinococcosis: How Do CT and MRI Perform in Comparison to Ultrasound? *PLoS Negl Trop Dis* 2012;6(10): e1880. doi:10.1371/journal.pntd.0001880
11. Shah D, Parikh H, Shah B, Banuprakash S, Shah J. Imaging Appearances of Hydatid Cyst. *Ind J Radiol Imag* 2006;16:4:533-5
12. Knoch H, Helbig M, Schreen J, Tasman AJ. Cystic space occupying lesion of the neck soft tissue: Cave Echinococcosis. *HNO* march 1999;47(3):188-91
13. Chakrabarti I, Goswami B. Primary hydatid cyst of the neck diagnosed by aspiration cytology. *Trop Parasitol* 2012;2(2):127-28.
14. Paksoy Y, Ödev K, Şahin M, Arslan A, Koç O. Percutaneous Treatment of Liver Hydatid Cysts: Comparison of Direct Injection of Albendazole and Hypertonic Saline Solution. *AJR* 2005;185:727-34
15. Mujtaba S, Faridi N, Haroon S. Primary hydatid cyst of the neck *J Coll Physicians Surg Pak*. 2013;23(10):811-2.