

## Case Report

### A Disseminated Peritoneal Melanosis in a 71-year-old Ethiopian Woman Diagnosed with Ovarian Mucinous Adenocarcinoma: Case Report

Binyam Esayas\*<sup>1</sup>, Shiferaw Negash<sup>2</sup>, Husnia Lobi<sup>3</sup>, Motuma Gutu<sup>4</sup>, Tesfaye Adem<sup>5</sup>, Selam Gebrechristos<sup>6</sup>, Isa Salo Abdo<sup>7</sup>

<sup>1,3,4,5,6</sup>Assistant professor in Obstetrics and Gynecology, Addis Ababa University, department of Obstetrics and Gynecology

<sup>2</sup>Associate professor in Obstetrics and Gynecology, Addis Ababa University, department of Obstetrics and Gynecology

<sup>7</sup>Pathology Resident, Addis Ababa University, department of Pathology

\*Corresponding author email: naniesayas@gmail.com

#### Abstract

**Background:** Peritoneal melanosis is a benign disease that can be encountered during laparotomy. We are reporting this extremely rare condition with less than 20 cases reported in the world literature and also in Ethiopia. This condition is usually incidental finding during laparotomy and is mainly associated with ovarian lesions.

**Case:** A 71-year-old woman presented to gynecology out-patient department with abdominal swelling of 1-year duration. Abdominopelvic mass with gross ascites detected, likely arising from the ovary. She then underwent a unilateral salpingo-oophorectomy followed by total abdominal hysterectomy and unilateral salpingo-oophorectomy with a high index of an advanced ovarian cancer. The intraoperative findings showed a diffuse dark pigmentation involving the greater omentum, the visceral peritoneum, and serosa of the large and small bowel segments. The histopathology revealed a moderately differentiated mucinous adenocarcinoma with benign peritoneal melanosis. With this diagnosis she completed adjuvant chemotherapy.

**Conclusion:** Though occurrence of peritoneal melanosis with ovarian adenocarcinoma doesn't suggest different treatment or prognosis. We recommend surgeons during laparotomy to be aware of this benign condition during laparotomy. Little is known about this rare condition therefore, women with peritoneal melanosis should be followed closely for the long-term outcome

**Keywords:** Peritoneal melanosis, Mucinous adenocarcinoma, Ovarian tumor

**Citation :** Esayas B, Negash S, Lobi H, et al , A Disseminated peritoneal melanosis in a 71-year-old Ethiopian woman diagnosed with ovarian mucinous adenocarcinoma: Case Report. *Ethiop Med J* 63 (1) 343-348

**Submission date :** 20 August 2024 Accepted: 13 December 2024 Published: 1 January 2025

#### Introduction

Peritoneal melanosis is a rare condition characterized by dark brown pigment deposition in the peritoneum. Benign peritoneal melanosis may occur in association with other congenital cystic conditions such as ovarian dermoid, peritoneal, enteric duplication cysts, or even gastric triplication (1).

There are few cases of peritoneal melanosis associated with mucinous cystadenoma of the ovary and peritoneal melanosis associated with serous carcinoma of the ovary (2,3,4). This condition is usually incidental finding during laparotomy and is mainly associated with ovarian lesions (2).

Different literatures mention rupture of ovarian der-

moid cyst or melanogenic tumors, ill-migrated neural crest remnants or pinched-off multipotent mesothelial cells of the peritoneum during developmental period and differentiation of coelomic epithelium as possible causes for the development of peritoneal melanosis (2,6,7,8,9).

We report a case of peritoneal melanosis associated with a mucinous cystadenocarcinoma of the ovary. This case has been reported following the SCARE criteria 2020 (5).

#### Case report

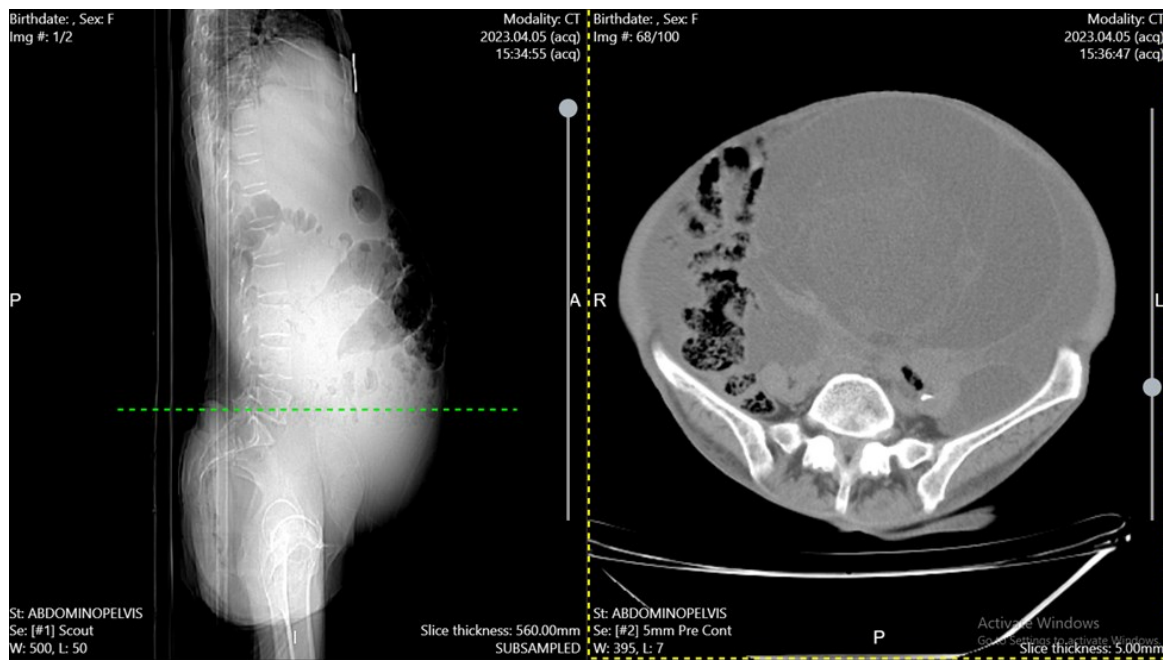
A 71-year-old para 12 Abortion 0 woman presented with progressive abdominal swelling of 1 year duration. She has associated early satiety, loss of appetite, un-

quantified but significant weight loss and bilateral lower leg swelling.

On physical examination, she was generally sick looking, cachectic, and in pain with an Eastern Cooperative Oncology Group (ECOG) performance status of 3. The vital signs were unremarkable.

On abdominal examination, a grossly distended abdomen with positive fluid thrill and shifting dullness suggestive of gross ascites. There was a 24 weeks' size and ballotable abdominopelvic mass. Except for the cul-de-sac bulge on digital vaginal exam the rest of the pelvic

and rectal examinations were unremarkable. The tumor markers had moderate increase in CA125 (86.4 U/mL) level; AFP, CEA, CA19.9, CA15.3 were all within normal ranges. Abdominopelvic ultrasound and CT scan showed a 24.3 cm \*13.5 cm\*18.5 cm abdominal pelvic mass with solid and cystic lesions with calcification likely arising from the right adnexa and with metastatic deposits on the omentum. Otherwise, the uterus, the left adnexa, the liver, large and small bowel were unremarkable (Figure 1).



**Figure 1:** Abdominopelvic CT scan shows abdominal pelvic mass with solid and cystic mass with calcification likely from right adnexa,

As the patients had poor functional status with ECOG performance status of 3, predominantly cystic ovarian mass inaccessible for core needle biopsy and absence of frozen section, laparotomy with short operative time was decided for tissue diagnosis.

After necessary preoperative preparation and preanesthetic evaluation done and the abdominal cavity entered through the midline abdominal incision extending from suprapubic area to the level of 4cm above the umbilicus. The Intra operative finding showed, about 10 liters' dark mucoid peritoneal fluid which was sucked out. There was dark pigmentation of the omentum, mesentery, the visceral and parietal peritoneum. There were multiple

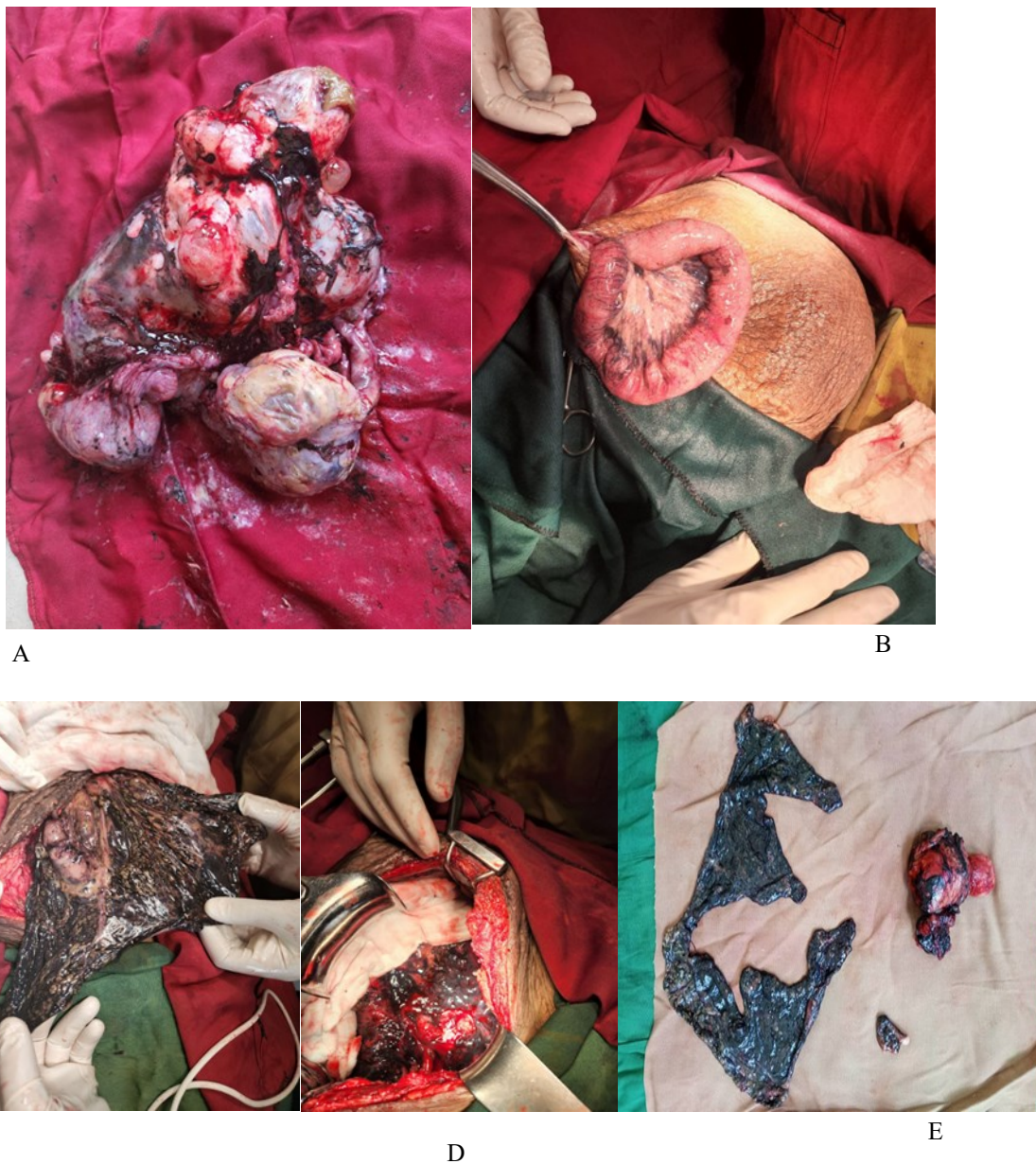peritoneal nodules of size less than 1cm in diameter on the anterior abdominal wall on the left lower quadrant. There was about 25cm by 20cm left complex ovarian mass (with continuous leakage of mucinous content to the peritoneal cavity) with filmy adhesion to the anterior abdominal wall and bladder (Figure 2). Due to her poor performance status, the surgery was limited to unilateral salpingo-oophorectomy and the tissue sent for histopathological examination.

The histopathology reported revealed a moderately differentiated mucinous adenocarcinoma. Following surgery, she was on high protein diet and an additional nutritional support for two months.

After her performance status [has shown an improvement with ECOG performance status of 1](#), a complete cytoreductive surgery was made.

The intraoperative finding showed, around 300ml ascitic fluid, the same dark hyperpigmentation of both the visceral and parietal peritoneum including the omentum and mesentery. Atrophied right ovary with unremarkable uterus. There was a diffuse deposit on the parietal peritoneum of right anterolateral abdominal wall and

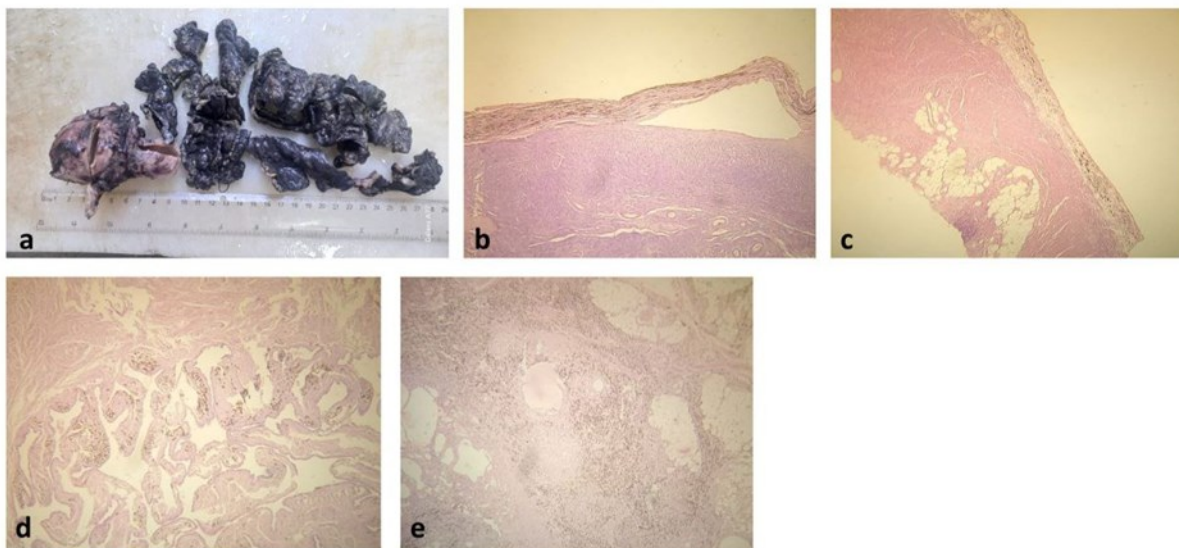
multiple small nodules of size about 1cm on the omentum (Figure 2). The cytoreductive surgery performed carefully by the team of gynecologic surgeons lead by the same senior gynecologic oncologist and there were no intra- or postoperative complications.



**Figure 2.** A) multi lobulated ovarian mass with ruptured capsule, there are black colored staining of the surface. B) there is black staining of the mesentery and bowel surface C), D) and E) Dark brown pigmentation of omentum pelvic peritoneum uterus, ovarian surface and Appendix

The histopathology reported by the same pathologist showed the uterus being unremarkable, sections from the left ovary, tube, appendix, omentum, and the anterior abdominal wall lesions showed surface histocytes with dark brown pigment deposition. No features of malignant cell seen (Figure 3).

Currently, the patient is on her 8<sup>th</sup> month after the second surgery and she had smooth postoperative course with no major complaints and having good performance status. she was given carboplatin and paclitaxel adjuvant chemotherapy as per the local guideline.



**Figure 3:** (a) gross picture of the uterus, cervix, unilateral ovary and fallopian tube, along with appendix and omentum showing extensive darkening of external surfaces. (b) and (c) (H&E) brownish coarse pigment deposition on the surfaces of ovary and appendix respectively. (d) (H&E) pigment is seen in the plicae of the fallopian tube, and (e) (H&E) abundant pigment laden macrophages also present in the omentum.

#### Discussion-

A case of peritoneal melanosis secondary to the rupture of a bilateral ovarian cystic teratoma was reported by Afonso in 1962 (1). Melanosis peritonei is an extremely rare condition with around 20 reported cases in the English literature. In most cases the clinical presentation and intraoperative finding was similar to our case (3,4,7).

Although peritoneal melanosis is considered a benign condition, it is usually associated with other disorders like desmoid ovarian cyst, enteric duplication cyst, gastric triplication, and ovarian cystadenomas. More than half of the peritoneal melanosis is associated with ovarian lesions. There was a case where peritoneal melanosis was associated with malignant ovarian cancer. Peritoneal melanosis mostly affects females, age 6 month to 28 years, women age 42-79 and male patients were rare in cases reported (3,7).

Pigmentation of peritoneal melanosis may result from the rupture of ovarian dermoid cysts or of melanogenic tumors into the abdominopelvic cavity or hemorrhage in the teratoma containing the gastric

mucosa and gastric ulceration (6,7). However, those theories are only validated for cases associated with a ruptured ovarian teratoma. Another theory hypothesized that peritoneal melanosis might appear as a final result of multifactorial etiologies such as ill-migrated neural crest remnants (8) or pinched-off multipotent mesothelial cells of the peritoneum during the developmental period (9). It was also suggested that both the serous lining and pigmented peritoneal mesothelial cells originate from the coelomic epithelium, and that differentiation occurs under local or unknown factors (2).

Endometriosis, peritoneal lipofuscinosis, and malignant conditions, including metastatic malignant melanoma, should be excluded during diagnosis. Endometriosis can be easily distinguished from peritoneal melanosis by the presence of glands surrounded by endometrial stroma and hemosiderin deposits. Peritoneal lipofuscinosis differs from peritoneal melanosis in that histochemically demonstrated pigment is not melanin but lipofuscin (9).

The main differential diagnosis of peritoneal melanosis is metastatic melanoma. Metastatic melanoma

has a poor prognosis in comparison with benign peritoneal melanosis. Metastatic melanoma is differentiated by identifying the primary lesion, and clear examination of the skin, the anorectal canal and the ocular epithelium. Microscopically, both peritoneal melanosis and metastatic melanoma share similar presentation but in case of metastatic melanoma cells hematoxylin and eosin-stained sections is used and diagnosis can be confirmed using Immunohistochemistry (IHC) with S-100 and HMB-45 (1,10,11).

Despite the presence of peritoneal melanosis, management of the primary cases in the literature wasn't changed. In the majority of these cases, they were followed for 6 months up to 5 years with no change in the course of the disease (2,3,4,7).

### Conclusion

This is a case report depicting peritoneal melanosis with moderately differentiated mucinous adenocarcinoma. We urge surgeons to be aware of this benign condition during laparotomy as it could be an incidental finding. Though little is known about the clinical implication of peritoneal melanosis in association with ovarian tumor, patients with this diagnosis should be followed for long term outcome..

### Consent to publish

Consent for publication was taken from the patient.

### Authors' Contribution

Dr Binyam Esayas: Assistant professor in Obstetrics and Gynecology, Addis Ababa University, department of Obstetrics and Gynecology: He has written the article, and participated in the surgery.

Dr Shiferaw Negash: Associate professor in Obstetrics and Gynecology, Addis Ababa University, department of Obstetrics and Gynecology: He has participated in the surgery, and supervised the writing of manuscript.

### References

1. J.F. Afonso, G.M. Martin, F.S. Nisco, R.R. de Alvarez, Melanogenic ovarian tumors, *Am. J. Obstet. Gynecol.* 84 (5) (1962), [https://doi.org/10.1016/0002-9378\(62\)90162-X](https://doi.org/10.1016/0002-9378(62)90162-X).
2. Jaworski RC, Boadle R, Greg J, Cocks P. Peritoneal "melanosis" associated with a ruptured ovarian dermoid cyst: report of a case with electron-probe energy dispersive X-ray analysis. *Int J Gynecol Pathol.* 2001 Oct;20(4):386-9. doi: 10.1097/00004347-200110000-00012. PMID: 11603224.
3. Kim SS, Nam JH, Kim SM, Choi YD, Lee JH. Peritoneal melanosis associated with mucinous cystadenoma of the ovary and adenocarcinoma of the colon. *Int J Gynecol Pathol.* 2010 Mar;29(2):113-6. doi: 10.1097/PGP.0b013e3181bb4182. PMID: 20173496.
4. Kim NR, Suh YL, Song SY, et al. Peritoneal melanosis combined with serous cystadenoma of the ovary: a case report and literature review. *Pathol Int* 2002; 52:724–9. DOI: [10.1046/j.1440-1827.2002.01405.x](https://doi.org/10.1046/j.1440-1827.2002.01405.x)
5. R.A. Agha, T. Franchi, C. Sohrabi, et al., The SCARE 2020 guideline: updating consensus surgical Case Report (SCARE) guidelines, *Int. J. Surg.* 84 (2020) 226–230, <https://doi.org/10.1016/j.ijssu.2020.10.034>.
6. C.S. Lim, J.F. Thompson, P.R. McKenzie, S.W. McCarthy, R.A. Scolyer, Peritoneal melanosis associated with metastatic melanoma involving the omentum, *Pathology* 44 (3) (2012) 255–257, <https://doi.org/10.1097/PAT.0b013e3283514015>.
7. Mhand, Mohammeda,b,\*; Obed, Rocksona,b; Harouachi, Abdelhakima,b; Haloui, Anasb,c; Bouhout, Tariqa,b; Bennani, Amalb,c; Serji, Badra,b; Harroudi, Tijani EL.a,b. Peritoneal melanosis associated with

Dr Husnia Lobi : Assistant professor in Obstetrics and Gynecology, Addis Ababa University, department of Obstetrics and Gynecology: She has participated in the surgery, and supervised the writing of manuscript.

Dr Motuma Gutu: Assistant professor in Obstetrics and Gynecology, Addis Ababa University, department of Obstetrics and Gynecology: He has helped writing the article.

Dr Tesfaye Adem: Assistant professor in Obstetrics and Gynecology, Addis Ababa University, department of Obstetrics and Gynecology: He has helped writing the article.

Dr Selam Gebrechristos: Assistant professor in Addis Ababa University, department of Pathology: Interpretation of histological data, preparation of pathology slides and confirm the histological diagnosis.

Dr Isa Salo Abdo: MD, Pathology Resident, Addis Ababa University, department of Pathology: Interpretation of histological data and preparation of pathology slides

### conflict of interest

The authors declare that they have no competing interests.

### Funding

No funding was available

### Data Availability

Data sharing does not apply to this article as no new data were created or analyzed in this study.

- serous carcinoma of the ovary: A case report and literature review. *Annals of Medicine & Surgery* 81(), September 2022. | DOI: 10.1016/j.amsu.2022.104452
8. Reccia I, Pisanu A, Podda M, Uccheddu A. An uncommon presentation of metastatic melanoma. *Medicine (United States)*. vol. 94. 2015. doi:10.1097/MD.0000000000000319
  9. White J, Chan YF. Lipofuscinosis peritonei associated with pregnancy-related ectopic decidua. *Histopathology* 1994; 25: 83–85. DOI: [10.1111/j.1365-2559.1994.tb00602.x](https://doi.org/10.1111/j.1365-2559.1994.tb00602.x)
  10. Ohsie SJ, Sarantopoulos GP, Cochran AJ, Binder SW. Immunohistochemical characteristics of melanoma. *J Cutan Pathol*. 2008 May;35(5):433-44. doi: 10.1111/j.1600-0560.2007.00891.x. PMID: 18399807.
  11. Saliba E, Bhawan J. Aberrant Expression of Immunohistochemical Markers in Malignant Melanoma: A Review. *Dermatopathology (Basel)*. 2021 Aug 3;8(3):359-370. doi: 10.3390/dermatopathology8030040. PMID: 34449584; PMCID: PMC8395931.