

**CASE REPORT****PULMONARY COCCIDIOMYCOSIS PRESENTING AS A MASS,  
AN UNCOMMON DISEASE ENTITY IN ETHIOPIA**Girmay Hagos, MD<sup>1</sup>, Reiyee Esayas, MD<sup>1</sup>**ABSTRACT**

*Coccidiomycosis is a disease caused by the spores of the fungi coccidioides immitis and pulmonary coccidiomycosis comes after inhalation of the spores which are mainly found in desert areas of the United States, central and South America.*

*Reported cases from outside the endemic areas have always history of travel to these areas. There are no reports so far from Ethiopia or the whole Africa. We report here a case of pulmonary coccidiomycosis with no history of travel to such areas,*

*A 24 years old female patient from Samre, South-Eastern Tigray, presented with right side chest pain and productive cough of yellowish sputum which sometimes is blood streaked. She had completed anti-tuberculosis treatment without any improvement. With a preliminary diagnosis of pulmonary mass, surgical exploration was made and histology of the excised tissue showed appearances consistent with pulmonary coccidiomycosis. There was marked clinical and radiological improvement after three weeks of treatment with ketoconazole. Though there are no reported cases from Ethiopia and Africa as a whole, Coccidiomycosis should be considered as differential diagnosis especially for patients from arid areas like that of our patient before any empirical treatment*

**INTRODUCTION**

Coccidiomycosis is a disease caused by the soil-inhabiting spores of the fungi coccidioides immitis. , which is often found in desert regions with incubation period of 7-21 days. About 60 % of infections cause no symptoms and the rest 40% symptoms range from mild to severe. Individuals with compromised immune status are at high risk for pulmonary coccidiomycosis as well as for disseminated and cutaneous forms of the disease.

The disease can have an acute, chronic or disseminated form. Acute pulmonary coccidiomycosis is almost mild, with few or no symptoms and may resolve without treatment, where as chronic pulmonary coccidiomycosis can develop 20 or more years after initial infection and may present as lung abscess, empyema, bronchopleural fistula or scarring (fibrosis) including as mediastinal mass. (1,2,4) Rates of infection are highest during dry months

and are accentuated when soil is disturbed by wind-storms. Exposure to contaminated balls of cotton or other fomites can result in infection beyond the endemic region, although rarely. Person to person transmission of pulmonary infection has not been reported. (5,6)

Coccidiomycosis is usually asymptomatic. Those who become ill usually experience self-limited pulmonary syndromes. However, few patients develop complications or progressive forms of infection that display a broad variety of manifestations and pose difficult problems in management for the clinician (2, 3, 4)

Diagnostic workup for pulmonary coccidiomycosis includes proper history taking and physical examination, imaging studies with X-Ray finding of primary pulmonary disease including variable nonspecific infiltrates, hilar adenopathy and pleural effusions. Findings such as cavities and nodules demonstrate progression in to the complicated or residual stage of pulmonary coccidiomycosis. Although radiographic fea-

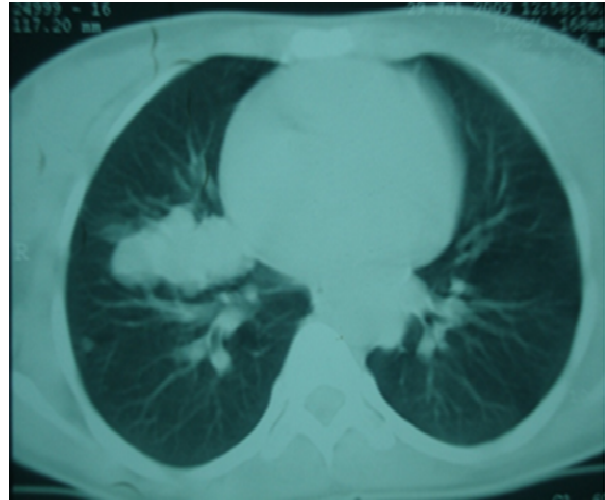
<sup>1</sup>Department of Surgery, Mekele University, Mekele Ethiopia

tures can be diagnostic, proof of coccidiomycosis relies on histopathological, mycological and serological evaluation. Pathological diagnosis requires the demonstration of endospore-forming spherules. (4,5,6).

Treatment options for coccidiomycosis depend on the severity of the disease and the treatments generally consist of amphotericin B deoxycholate or azoles. Amphotericin is for the severe form of coccidiomycosis while Ketoconazole, Fluconazole and Itraconazole are for mild form of the disease. (6-8)

#### **Case presentation:**

A 24 year old female patient from Samre, South-Eastern Tigray presented with productive cough of yellowish sputum which sometimes is blood stained, right sided chest pain and unquantified weight loss of 6 months duration. Complete blood count and organ function tests were normal. She was screened for HIV and was negative. Sputum was also negative for AFB. Culture and serology was not done due to limited set up. She completed anti-tuberculosis treatment without any improvement. Chest x-ray and CT scan showed right parahilar mass (Fig 1 and 2).

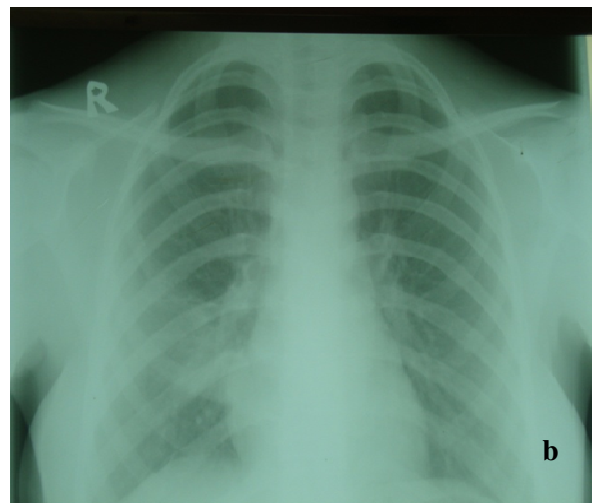
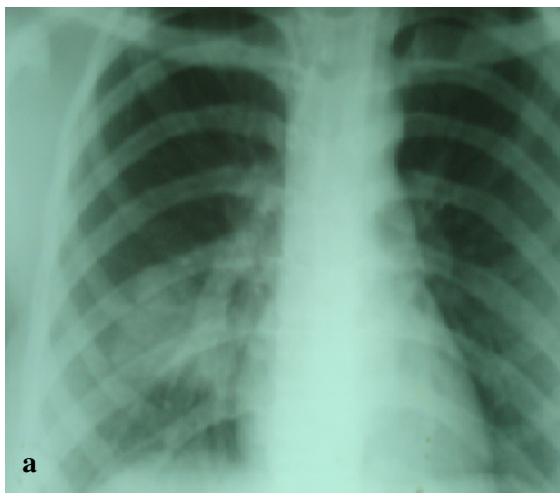


**Fig.1:** Pulmonary coccidiomycosis presenting as Right parahilar mass on CT-scan

Right thoracotomy was done with preliminary diagnosis of pulmonary mass. The patient made an uncomplicated recovery from her operation and was discharged after 5 days of hospital stay.

Histopathology of the excised tissue reported spherules with retractile walls and internal organizations that it are consistent with coccidioidomycosis. The patient had completely improved after treatment with ketokonazole 200mg twice daily for three weeks and was followed for six months which is the standard treatment.

On subsequent outpatient follow up the surgical wound had healed without any complications and had marked clinical and radiological improvement with no further symptoms (Fig 2).



**Fig.2:** Chest X-ray Pulmonary Coccidiomycosis before (a) and after (b) treatment with ketoconazole for three weeks.

**Conclusion.:** This particular case showed that coccidioidomycosis could also be found in cases without any history of travel to the western hemisphere and that this disease, although rare, could be one cause of pulmonary disease in Africa, particularly in dry parts of northern Ethiopia. So the available diagnostic modalities should be carried out including thoracoscopic or open air biopsy if the facility permits before initiation of empirical treatment.

**Consent:** Written informed consent was found from the patient for possible publication of this case report and for the pictures posted.

## REFERENCES

1. Lee Goldman, Andrew Schafer. Goldman's Cecil Medicine, 24<sup>th</sup> ed. Saunders Canada, 2011.
2. Tomsikova A. A case of coccidioidomycosis in Plzen. Cesk Epidemiol Mikrobiol Imunol. 1993 Jun;42(2):83-6.
3. Sherwood L.Gorbach and et.al. The 5-minute infectious disease consult. Lippincott Williams & Wilkins Philadelphia 2001.
4. Centers for Disease Control and Prevention (CDC) Increase in Coccidioidomycosis - Arizona, 1998-2001. MMWR.2003;52(06):109-112.
5. Osaki T et al. Pulmonary coccidioidomycosis that formed a fungus ball with 8-years duration. Intern Med. 2005 Feb;44(2):141-4.
6. Rady MY, Lopez A, Patel BM, and Larson JS. Pyo-mediastinitis: A complication of pulmonary coccidioidomycosis. Can J Infect Dis. 2003 May-Jun; 14(3): 170–172.
7. Spinello M. et al. Pulmonary coccidioidomycosis. Seminars in respiratory and critical care medicine. 2008: 29 (2).
8. Valdivia L et al. Coccidioidomycosis as a Common Cause of Community-acquired Pneumonia. Emerging infectious disease.2006 June:12(6).