

Reiye Esayas Mengesha, Reintraut Brumeister Rother. *Ethiop Med J*, 2015, Vol. 53, No. 3

## CASE REPORT

### MANAGEMENT OF PHEOCHROMOCYTOMA IN THE ABSENCE OF ALPHA BLOKERS: A CASE REPORT FROM AYDER REFERRAL HOSPITAL

Reiye Esayas Mengesha, MD<sup>1</sup>, Reintraut Brumeister Rother, MD<sup>2</sup>

#### ABSTRACT

*A 13-year-old girl with right adrenal pheochromocytoma pretreated with Nifedipine, underwent surgical removal of the tumor. General anesthesia with Propofol infusion and pethidine analgesia was performed. To control the blood pressure (BP), Nitroglycerine infusions were administered successfully. Following the ligation of the adrenal veins, patient was hypotensive and inotropic support was required. This case report showed that in the absence of alpha blockers and short acting drugs the surgery could be done with a very good follow up and Nitroglycerine as antihypertensive.*

**Keywords:** general anesthesia; pheochromocytoma; Alpha blockers; Nitroglycerine;

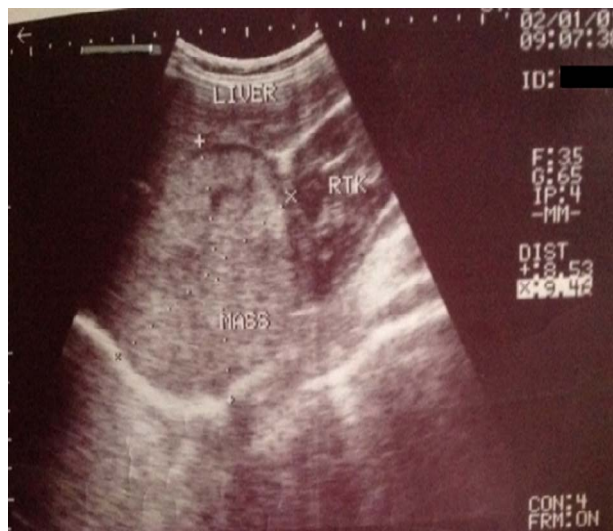#### INTRODUCTION

Pheochromocytoma is one of the surgical conditions where the medical treatment (preparation) is challenging. Traditionally non-selective  $\alpha$ -adrenoceptor blockers are used to control the hypertension but much more cheaper and available calcium channel blockers can be used in setups like ours.

#### CASE REPORT

A 13 yrs old female patient presented with exacerbation of paroxysms of palpitation, excessive sweating, headache, nausea and none projectile vomiting of ingested matter of two years duration. She had associated occasional fainting episodes and reddish discoloration of urine with dysuria. On physical examination, her BP was 160/100 mmHg. CBC (complete blood count) with differentials, urine analysis, thyroid function tests and serum electrolytes were determined and found to be within normal range.

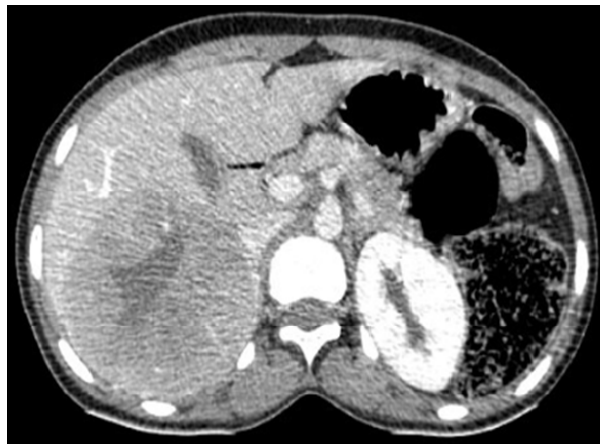Abdominal ultrasound revealed 8.5x9.5cm right adrenal mass (Fig.1) and CT of abdomen showed a 9 cm diameter right adrenal capsulated mass with no invasion to the surrounding structures (Fig. 2,3).



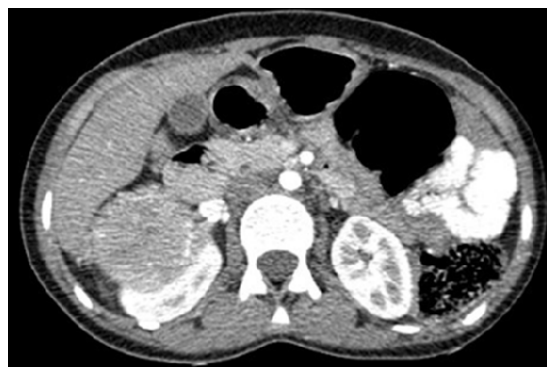**Fig.1.** Abdominal Ultrasound showing right suprarenal mass.

<sup>1</sup>Department of Surgery, Mekelle University, Ethiopia.

<sup>2</sup>Department of Anaesthesia, Mekelle University, Ethiopia.



**Fig.2.** Abdominal CT showing capsulated right suprarenal mass.



**Fig.3.** Abdominal CT showing right suprarenal mass flattening upper pole of the right kidney

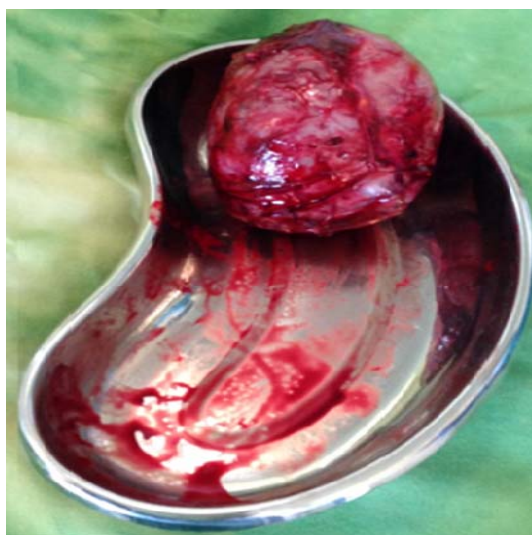Twenty four hour urine catecholamine and metanephrine were determined and the results were as depicted on Table1.

**Table1:** 24-hour urine catecholamine and metanephrine values

Test	Finding	Normal value
Metanephrine	1117+ $\mu$ g/24hrs	<400
Metanephrine/creatinine(urine)	1661+ $\mu$ g/g	33-145
Normetanephrine	16610+ $\mu$ g/24hrs	<800
Normetanephrine/creatinine(urine)	24695+ $\mu$ g/g	95-375
Vanillylmandelic acid	78.5+++mg/24hrs	<6
Vamillylmandelic acid/creatinine-	117+mg/g	<8.2

With all these findings the patient was admitted and started on oral Nefidipine 10mg BID, as alpha adrenergic blockers were not available in the market. During the 8 hour of fasting period preoperatively, i.v. (intravenous) crystalloid infusion was administered and to diminish the anxiety diazepam 10 mg was administered on call to the operation theatre. The preinduction HR(heart rate) and BP values were 106 beats/min and 135/70 mmHg, respectively.

Through right sub-costal incision the abdomen was entered, the right triangular ligament was divided and the peritoneum lateral to the hepatic flexure was incised to expose the adrenal. Dissection was started from the medial side developing a plane between the adrenal and IVC (inferior vena cava). There were small veins draining in to the renal vein, which were divided after ligation. The main adrenal vein draining to the postrolateral side of IVC was ligated and divided then the mass was excised in to two and sent for pathologic exam. ( Fig. 4).



**Fig.4.** Specimen of the excised right adrenal gland

**Anesthesia:** Before induction, BP was 135/70 mmHg, HR was 106/min, HB (hemoglobin) was 14.2 g/dl and RBS (random blood sugar) was 198 mg/l. Patient was induced with i.v. Propofol 120 mg, Vecuronium 0.2 mg (priming dose), Pethidine 40 mg, and Succinylcholine 75 mg. After induction, the BP and HR were 130/68 mmHg and 110/min respectively.

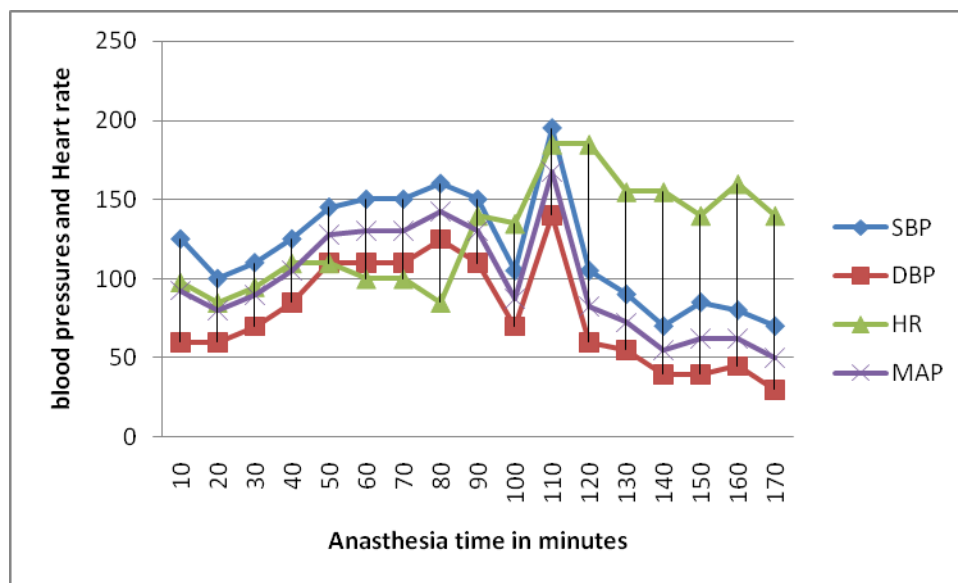
Maintenance of anesthesia was done with continuous Propofol i.v. (with perfusor) 50-100mg/h, Pethidine iv bolus 40 mg each 20-30 min (5 doses) and Vecuronium iv bolus: 1.5 -1mg (5doses). Fluid was maintained with 8ml/kg/hour RL (Ringers Lactate). Estimated blood loss was replaced with RL in a ratio of 1:3, 20 ml of Glucose 40% was added in the maintenance fluid since the RBS had decreased intraoperatively to 83 mg/dl.

Patient was ventilated with manual controlled ventilation with 100% O<sub>2</sub> and monitored with ECG (electrocardiography), BP, O<sub>2</sub> saturation, CO<sub>2</sub> and RBS. During Course of anesthesia, O<sub>2</sub> saturation ranged from 98-100%, CO<sub>2</sub> from 28-35 mmHg, RBS 83-92 mg/dl. BP during the first hour was 130/65 - 160/70 without additional medication and HR 80-130/min. There were no irregularity on ECG and the heartbeat was regular with sinus rhythm.

When the tumor was manipulated, BP fluctuated (highest being 200/140 mmHg). HR raised up to 190/min. Hydralazine bolus of 4 mg was repeated 3 times but did not decrease BP sufficiently. Nitroglycerine infusion (5mg in 100 ml Glucose 5%) decreased the BP to 120/60 mmHg (total dose of 2 mg).

After ligation of the adrenal vein, the BP dropped immediately to 60/38 mmHg – 70/40 mmHg (fig.5), and MAP (mean arterial pressure) below 60mmHg. Adrenaline as i.v. bolus (0.1mg) was repeatedly (three times) administered making the BP 80/50 mmHg.

The total urine output intraoperatively was 700 ml (in 2 and half hours). At the end of the operation the child was awake, following commands but she was hypoventilating. Hence, the patient was transferred while intubated to the ICU, where she was put on mechanical ventilator for 3 and half hours.



**Fig.5. Time course changes in hemodynamic parameters.** Systolic arterial pressure, diastolic arterial pressure, heart rate, mean arterial pressure. 0, before induction; 10 min, after induction and intubation; 30 min, surgery started; 110 min right adrenal vein ligation; 150 min, surgery finished.

**Immediate postoperative management:** Since the BP was persistently low (MAP below 60mmHg) adrenaline perfusion was commenced with initially 0.1microg/kg/min. Dose reduced during the next 3 hours to 0.008microg/kg/min. The BP stabilized (90/70 -105/75 mmHg) and adrenaline was stopped after 15 hours.

The child was under mechanical ventilation for 3 and half hours. Then after, she was fully awake with sufficient spontaneous breathing she was extubated (25mg hydrocortisone i.v. was given before extubation). She was put on nasal O<sub>2</sub> 1liter and could maintain O<sub>2</sub> saturation of 92-95%.

Postoperative temperature was 36.4 °C, RBS 78mg/dl, and Hct (hematocrite) was 36.4%. On the 1<sup>st</sup> postoperative day, she took 3liters of RLand 20ml Glucose 40% in each bag for 24 hours. For pain relief, Tramadol 50 mg i.v. TID and Pethidine 25mg i.v. PRN was given.

With this treatment she remained stable, with good urine output (1150ml in 16 hours), RBS ranging 80-130 mg/dl, and fever free, except 1 record of 38.2C. Electrolytes and renal function tests were within normal range. She started oral intake of fluids, was mobilized and complained only of mild pain on the surgical site. She was transferred from the ICU on the 2<sup>nd</sup> postoperative day.

The patient was discharged from the hospital on the 8<sup>th</sup> postoperative day active and stable and she was not in any kind of medication. Appointment to come to the referral clinic for follow up was given.

## DISCUSSION

Pheochromocytoma is a rare catecholamine secreting tumor that arises from chromaffin cells. Patients present with paroxysmal hypertension, headache, palpitation and excessive sweating. Surgery is the mainstay of treatment and possible cause of death if patient is not well prepared preoperatively and followed well during and after surgery. All the pre operative, intraoperative as well as postoperative managements determine the outcome of the surgery (1).

The management of any surgical patient with pheochromocytoma is a challenge even to the most experienced anesthesiologist. Although the incidence of phaeochromocytoma is very low (0.2–2 per 100,000 adults per year), complications may be severe (2).

Traditionally used preoperative antihypertensive drugs are the non-selective  $\alpha$ -adrenoceptor blocker Phenoxybenzamine and a  $\beta$ -adrenoceptor blocker, Propranolol (3). Agents like selective  $\alpha$ -adrenoceptor blockers, Doxazosin and Prazosin, and calcium channel antagonists have been used effectively (4). But, in countries like ours, most of these drugs are not available and it is wise to use the drugs at hand (5).

Our report shows a successful surgical removal of pheochromocytoma with the use of only Nefidipine and nitroglycerine as anti-hypertensives and this can be taken as a good option for setups like ours provided that there is a proper follow up of patients.

## REFERENCES

1. A. Luo, X. Guo, J. Yi, H. Ren, Y. Huang and T. Ye: "Clinical features of pheochromocytoma and perioperative anesthetic management" Chin. Med. J., Vol. 116, (2003), pp. 1527-1531
2. E.L. Bravo and R. Tagle: "Pheochromocytoma: state-of-the-art and future prospects. Endocr.Rev., Vol. 24 (2003), pp.539-553.
3. S.L.Chew: "Recent developments in the therapy of phaeochromocytoma" Expert. Opin.Investig.Drugs., Vol. 13, (2004) pp. 1579-1583.
4. T. Zelinka, B. Strauch, O. Petrak, R. Holaj, A. Vrankova, H. Weisserova, K. Pacak, and J. Widimsky Jr. "Increased blood pressure variability in pheochromocytoma compared to essential hypertension patients" J. Hypertens., Vol. 23, (2005), pp. 2033-2039
5. List of medicines for Ethiopia, 6th ed., Food, Medicine and Healthcare Administration and Control Authority of Ethiopia, Addis Ababa, September 2010.